The Decision-Making Process in Acute Type A Aortic Dissection: When to Replace the Aortic Arch

Alessandro Leone, MD, Luca Di Marco, MD, PhD, Giacomo Murana, MD, PhD, Giuditta Coppola, MD, Mariafrancesca Fiorentino, MD, Ciro Amodio, MD, Roberto Di Bartolomeo, MD, and Davide Pacini, MD, PhD

The decision-making process is crucial for the surgery of acute type A aortic dissection (AAAD). Often surgeons have to face different challenges, taking prompt decisions in emergency setting, during the pre- and intraoperative phase. Choosing if operate or not a patients with AAAD as well as the management of the dissected aortic arch can be challenging. Different factors need to be evaluated as: the patients age, the presence of organ malperfusion, the intimal tear location, and last but not least the surgeon personal experience in aortic surgery. During the last decade, different milestone steps have been achieved in aortic surgery as the antegrade perfusion of the aorta through different cannulation sites, open distal repair, antegrade selective cerebral perfusion, and systematic resection of the proximal intimal tear, allowing complex repair for dedicated team as well as simpler repair for not dedicated surgeons. We reviewed different scenarios and techniques used for the aortic arch replacement in patients with AAAD, taking into consideration that the aim of surgery is to save patients life.

Semin Thoracic Surg 31:691–696

Keywords: Acute dissection, Aortic arch, Elephant trunk

3D reconstruction of acute type A aortic dissection.

Central Message

We reviewed different scenarios and techniques used for the aortic arch replacement in patients with type A aortic dissection, considering that the aim of surgery is to save patients' life.

INTRODUCTION

Acute type A aortic dissection (AAAD) represents one of the most complex and life-threatening pathology of the thoracic aorta and is still considered a challenge for cardiothoracic surgeons.[1]

Mortality rates of medically managed type A acute aortic dissection are 20% at 24 hours after presentation, 30% at 48 hours, 40% at a week, and 50% at a month. Aortic rupture, stroke, visceral ischemia, and cardiac tamponade are the most common causes of death.[2]

There are many important aspects of the surgical management that still need to be clarified in order to refine selection criteria for each technique and to decide the extension of the aortic replacement. Some surgeons believe in a more conservative, tear-oriented, approach such as hemiarch or partial arch replacement.[3] Conversely, other authors suggest a more aggressive approach, such as total arch replacement with or

Cardiac Surgery Unit, Cardio-Thoracic-Vascular Department, S. Orsola Hospital, Alma Mater Studiorum, University of Bologna, Bologna, Italy

Disclosures: Authors have nothing to disclose with regard to commercial support.

Conflicts of Interest: None.

Address reprint requests to Alessandro Leone, MD, Cardio-Thoracic-Vascular Department, S. Orsola Hospital, University of Bologna, Via Massarenti n. 9, Bologna 40128, Italy. E-mail: leone.alessandro@yahoo.it

1043-0679/$–see front matter
https://doi.org/10.1053/j.semtcvs.2019.05.036

without the use of the frozen elephant trunk (FET) or classic elephant trunk technique.[4–6] The rationale behind this more invasive operation is to reduce the risk of late aneurysm's of the distal aorta and to avoid the progression of the pathology in the distal thoracic aorta, especially in young patients. The purpose is to discuss about the decision-making process in AAAD.

DECISION-MAKING PROCESS

The most important factor during this kind of surgery is the decision-making process during the preoperative phase. Surgeons often face the dilemma whether to operate or not a patient with AAAD associated with different comorbidities or with advanced age. This often happens in an emergency setting requiring a prompt decision.

The starting point and the basic concept for this kind of surgery are to save the patient's life, replacing the ruptured aortic segment and restoring the blood flow into the true lumen.

However, different variable influence the decision, like the patient's clinical status at presentation, the presence of malperfusion syndrome, the age, co-morbidities, the anatomy of the dissection, the intimal tear location, and last but not least the surgeon's personal experience. All this factors have to be carefully evaluated since that contraindications for this surgery have been progressively shifted from absolute to relative along the years, thanks also to the improvements in technologies and techniques and also to the growth of the global experience in this field.

ENTRY TEAR LOCATION

Young patients with no comorbidities are more likely to be subjected to an extensive repair of the thoracic aorta than the older ones, even if the final decision is determined by the entry tear location. The proximal portion of the thoracic aorta is the one that most frequently experiences rupture; therefore, a prompt replacement is mandatory. A preoperative assessment of the aortic root through the angio-CT scan and the echocardiogram is mandatory.

In young patients, an enlarged aortic root or the presence of the intimal flap near or around the coronary ostia can be considered an indication for an aortic root replacement, especially in presence of severe aortic regurgitation. Valve-sparing operations can be considered if the aortic leaflets are in good conditions and if there is a significant experience in the surgeon's background with these techniques, in order to obtain a successful repair.

Approximately 25–30% of patients present additional arch tears and/or proximal descending aorta re-entry sites.[7] In this case, especially in young patients, a total resection of the arch with the FET technique can be taken into consideration. On the other hand, in older ones, this kind of surgery can be considered too risky and the choice can be shifted to a more conservative approach as partial arch or hemiarch replacement. However, if the intimal tear is located in the arch, rapid dilatation and rupture can occur if the arch is not replaced. Thus, in this case, surgeons can be forced to a more aggressive approach, despite any comorbidity. In fact, the incidence of long-term events is closely influenced by the persistence of the false lumen, distally from the site of repair, which has been reported in 75–100% of cases. Moreover, the occurrence of additional entry tears is associated with an unfavorable prognosis.[8,9]

AGE

The age is probably the most important factor that influences the whole decision-making process in patients with AAAD. Due to the continuously increasing life expectancy, a growing number of elderly patients is affected by AAAD and frequently undergoes surgical procedures to repair it.

The International Registry of Acute Aortic Dissection (IRAD) found that age ≥70 years is a significant predictor of in-hospital surgical mortality.[10] In contrast, a meta-analysis published in 2011[11] focused on octogenarian patients showed satisfactory immediate survival rates after surgery and suggested a more conservative approach for emergency repair in this complex subset of patients.

In this specific cohort appears even more mandatory to consider biological age and clinical conditions at the time of surgery case by case. Moreover, we observed that long-term survival was not statistically different between males and females and was comparable with the normal life expectancy.[12]

Anyway, considering the short life expectancy, especially in octogenarians, priority should be given to preventing aortic rupture saving the patient life. Reducing cardio pulmonary, myocardial and visceral ischemia time, and cerebral perfusion time respectively in these kinds of patients makes the procedure safer and more appropriate even in dubious situations.

MALPERFUSION SYNDROME AND PREOPERATIVE CLINICAL STATUS

Malperfusion is the second most common lethal complication of acute aortic dissection following aortic rupture. Approximately one-third of AAAD patients shows preoperative malperfusion syndrome of different organ systems, and end-organ malperfusion can dramatically reduce the chances of successful outcome.[13,14] A prolonged time between the initial symptoms and the subsequent treatment negatively influences the postoperative course of patients with an irreversible end-organ ischemia.

In the IRAD registry,[15] early mortality in unstable patients was much higher compared to patients without unstable features, regardless of the type of intervention. Coronary malperfusion complicates 10–15% of patients with AAAD. Ischemic electrocardiogram abnormalities are observed in 17.3% of TAAD, and findings of myocardial infarction (new Q waves or ST segments) in 7.1%. Moreover, electrocardiogram changes may lead to a misdiagnosis of acute coronary syndrome and this may delay the diagnosis of AAAD.[16] In such patients, restoring the blood flow in the coronary arteries

should be considered either reimplanting the coronary ostia or with myocardial revascularization, even if this resulted to be preoperative predictors of mortality as demonstrated by Rampoldi et al.[10]

Cerebral malperfusion results from partial or complete occlusion of the arch vessels by the intimal flap and affects 5–14% of patients with AAAD. Different authors proposed a delayed surgical approach only if the neurologic status improved.[16–18] In our opinion, this has to be taken into consideration especially for younger patients, even if surgeons are often facing the issue of treating unconscious and intubated patients without any anamnestic data or evidence of stroke. In light of this, a total or a light arch replacement with single reimplatation of the supra-aortic vessels can restore the blood flow into the true lumen reperfusing the brain.

The mesenteric malperfusion is a rare entity, approximately 4–6%.[19,20] In such cases, the decision-making is challenging and remains controversial. Mesenteric malperfusion is associated with an increased hospital mortality, greater than 60%. Fortunately, in those who underwent surgical and/or endovascular procedures, the results were better with a mortality rate of 41.7%, which is still high.

One of the main issues with mesenteric malperfusion is the clinical presentation, since abdominal pain does not occur in more than 40% of patients, whereas about 20% of patients without mesenteric malperfusion experience abdominal pain. Therefore, subclinical presentations may be underestimated and only the CT scan can complete the diagnosis, showing the compression of true lumen in the descending and thoracoabdominal aorta.

Even if it has been reported that early reperfusion is critical for mesenteric malperfusion, it is not clear whether initial aortic repair or percutaneous procedures best accomplishes that purpose.[21–23] Some authors suggest a prompt thoracic aortic replacement followed by a second stage treatment of the residual malperfusion.[21,24] On the other hand, other authors recommend initial reperfusion by stent deployment followed by delayed central aortic repair[23] as showed in Figure 1. Surgical/hybrid therapy offers better results in terms of postoperative outcome; in-hospital mortality was 41.7%, 72.7%, and 95.2%, in patients who underwent surgical/hybrid, endovascular, and medical treatment, respectively. In addition, in patients with clinically evidence of visceral ischemia, the strategy of percutaneous fenestration with or without stenting, as an initial procedure, may prevent an ineffective open aortic repair, especially in high-risk patients or in patients in poor clinical conditions. Conversely, in patients with angio-CT scan evidence of malperfusion without significant advanced end-organ dysfunction or clinical evidence, proximal repair should be performed first.[23]

SURGEON PERSONAL EXPERIENCE

The impact of surgeons' personal experience on postoperative outcomes is not marginal, and this has been already demonstrated by different authors in different fields of cardiac surgery.[25,26]

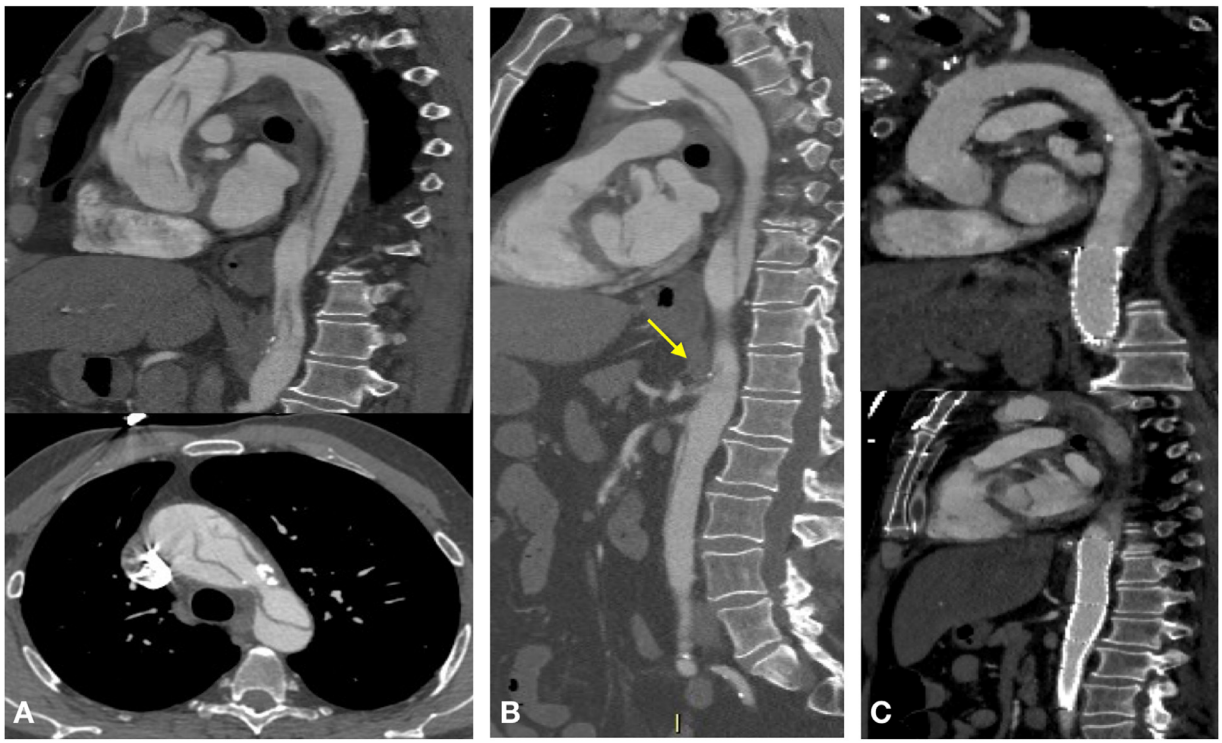

Figure 1. Patients with acute type A dissection. Presented in our department with abdominal pain and melena (A). True lumen compression at the CT scan (arrow B). The treatment option consisted in stent positioning followed by hemiarch replacement (C).

However, only few studies focused on aortic surgery, and in particular on AAAD. Andersen et al[27] demonstrated that the hospital mortality in AAAD was 33.9% when the operation was performed by different on-call surgeons and fell to 2.8% after establishment of "Thoracic Aortic Surgery Program" (TASP), a specific program, composed by a multidisciplinary team, dedicated mainly to aortic surgery.

Lenos et al reported their experience, showing the outcomes of patients either operated by "aortic surgeons" or "non-aortic surgeons."[28] They showed that patients operated by experienced aortic surgeons presented a significant better survival rate than patients operated by surgeons without experience in aortic surgery, even though they are experienced and skilled cardiac surgeons.

Bachet[29] commented assessing that major standards principles have been achieved in aortic surgery during the 2 last decades: antegrade perfusion of the aorta through the cannulation of the supra-aortic vessels or the proximal aorta, open distal repair, antegrade selective cerebral perfusion, and systematic resection of the proximal intimal tear. These principles represent significant progresses in cardiac and in particular in aortic surgery and a standardized approach, based on these principles, should be implemented since is not always possible to create a dedicated team on a particular pathology or area of interest, especially if it requires always a prompt availability of the surgeons.

MAIN SURGICAL TECHNIQUES FOR AAADS

Over time, the improvements in diagnostic techniques and the refinements in surgical strategies, significantly reduced hospital mortality (now estimated from 17% to 22%).[30,31] For this reason, a conservative tear-oriented approach aimed at performing the simplest and shortest operation to save the patient's life, has generally been adopted. Replacing the entire ascending aorta and hemiarch with resuspension of the aortic leaflets is the most common procedure. It represents a straight forward operation aim at reducing the circulatory arrest times to minimize postoperative mortality and morbidity.

However, in almost 30% of the cases, the rupture is located in to the arch or in the upper part of the descending aorta requiring a more extensive arch replacement.

Different techniques for arch replacement have been adopted and used, however is not always possible to perform extensive total arch interventions with liberal use of elephant trunk techniques (classic and frozen) that sometimes are necessary to improve long-term prognosis by contrasting late aneurysm formation at the distal aorta in young patients (Fig. 2).

On the other hand, in older patients, a partial arch replacement, performed in arch zone 2, reimplanting the left common carotid artery and the brachiocephalic trunk only and leaving in situ the left subclavian artery, can be considered as a feasible valid alternative. The fate of the distal aorta can be followed up with CT scan during the postoperative course and in the following months.

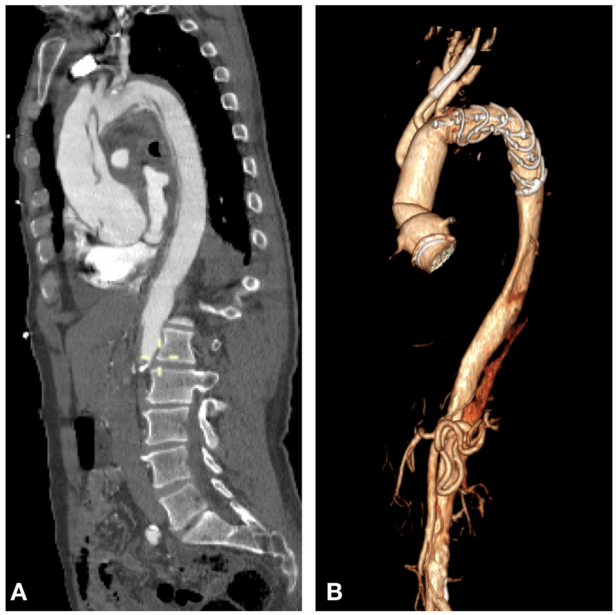

Figure 2. Young patient treated with Bentall procedure and FET technique (A pre, B post).

In case of further degeneration of the false lumen, or true lumen compression, the distal arch and thoracic aorta can be treated by left carotid to left subclavian bypass followed by endovascular extension (Fig. 3).

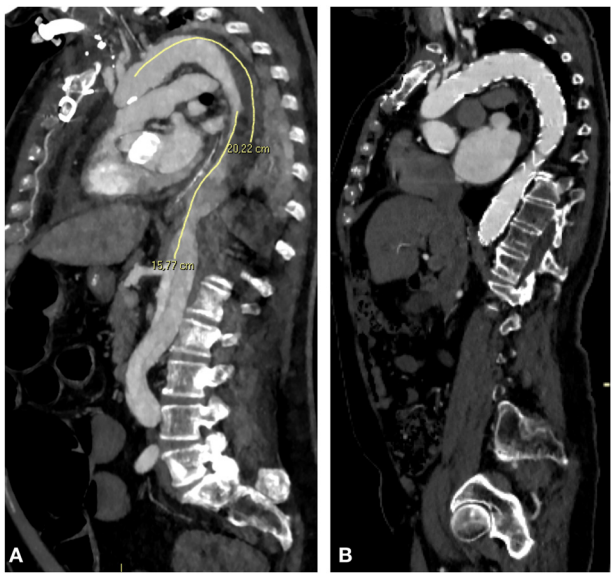

Figure 3. (A) Patient treated with partial arch replacement (ZONE 2), followed by endovascular extension and left carotid-subclavian bypass for abdominal pain during the postoperative course due to evolution of the dissection resulted in a true lumen compression (B).

Conventional key points of the procedure are represented by:

- Accurate analysis of the preoperative angio-CT scans, looking for entry tear location, re-entry in the downstream thoracoabdominal aorta, true and false lumen status, and origin of the visceral arteries.
- Institution of cardiopulmonary bypass using a central (distal ascending aorta, right axillary, innominate arteries, or carotid arteries) or peripheral (femoral artery) site for arterial cannulation.
- Myocardial protection is usually achieved with antegrade or retrograde intermittent infusion of cold crystalloid cardioplegia.
- Institution of hypothermic circulatory arrest from moderate (25−26°C) to deep (<25°C) core temperatures.
- Brain protection can be achieved with bilateral or unilateral antegrade selective cerebral perfusion under moderate hypothermia, but also by retrograde cerebral perfusion or deep hypothermia.
- Meticulous explorations of the aortic arch to check for primary or secondary entry tears.
- Complete exclusion of the intimal tear lesion.
- Ascending aorta with a hemi, partial, or complete arch replacement (with or without the use of the elephant trunk technique).
- Restart of the systemic perfusion immediately after the distal aortic arch anastomosis.

Recently a meta-analysis comparing hemiarch vs total aortic arch replacement in type A aortic dissection on 2221 patients[32] evidenced that cardiopulmonary bypass, aortic cross clamp, and circulatory arrest times were significantly longer in total arch replacement. In addition, there was no significant difference in terms of in-hospital mortality between the 2 groups. The only significant difference found between the 2 techniques was that hemiarch replacement was associated with a lower risk of postoperative renal dialysis. Similarly, Larsen et al[33] analyzing data from 1241 patients from the IRAD Registry did not find any significant difference in terms of in-hospital mortality between the hemiarch and the total arch replacement group.

Total arch replacement should be considered for patients with the primary entry tear located in the aortic arch or for patients with a pre-existing aneurysm of the aortic arch or proximal descending aorta. This technique requires the mobilization of the supra-aortic vessels, and the reimplantation procedure obviously requires longer visceral ischemia and cerebral perfusion times. Nevertheless, it remains a complex surgical procedure requiring surgical expertise to obtain good results.

The FET technique can also be considered in patients with distal aortic malperfusion and re-entry tears involving the distal arch or proximal descending thoracic aorta, which may result in prevention of the visceral organ malperfusion, reducing late events on the distal aorta. However, large series of this case treated with the FET technique, are still not reported in the literature.

Taking advantage of the distal stent graft segment of the hybrid prosthesis, a distal anastomosis can be more easily carried out at a more proximal arch avoiding the high risk of rupture or bleeding caused by the fragile dissected aortic wall.

According to a recent review analysis encountering the latest series on this argument, the operative mortality ranges from 3% to 16% in the FET group compared to a similar 5−23% mortality for the conventional repair[34]; similarly, the vascular domain of the European association of cardiothoracic surgery reported a postoperative stroke and spinal cord injury rates of 2.5−20% and 0−21%, respectively.[35] It is clear that this kind of technique has to be considered as an "advanced step" for dedicated aortic surgeons, in high-volume centers.

CONCLUSION

The aim of surgical therapy for AAAD is to save patient's life, and this objective should also be achieved considering all the different challenges in the decision-making process that any surgeon have to face in an emergency setting. All the information collected about the preoperative clinical status of the patients is crucial, and it should be currently managed by a patient-specific approach. Different options for the aortic arch replacement available should be tailored case by case keeping in mind the entry tear location, any malperfusion syndrome, the age of the patient, and also the expertise of the surgeon.

REFERENCES

1. Auer J, Berent R, Eber B: Aortic dissection: Incidence, natural history and impact of surgery. J Clin Basic Cardiol 3:151–154, 2000
2. Pacini D, Di Marco L, Fortuna D, et al: Acute aortic dissection: Epidemiology and outcomes. Int J Cardiol 167:2806–2812, 2013
3. Westaby S, Saito S, Katsumata T: Acute type a dissection: Conservative methods provide consistently low mortality. Ann Thorac Surg 73:707–713, 2002
4. Kazui T, Washiyama N, Muhammad BA, et al: Extended total arch replacement for acute type A aortic dissection: Experience with seventy patients. J Thorac Cardiovasc Surg 119:558–565, 2000
5. Urbanski PP, Siebel A, Zacher M, et al: Is extended aortic replacement in acute type a dissection justifiable? Ann Thorac Surg 75:525–529, 2003
6. Shrestha M, Fleissner F, Ius F, et al: Total aortic arch replacement with frozen elephant trunk in acute type A aortic dissections: Are we pushing the limits too far? Eur J Cardiothorac Surg 47:361–366, 2015
7. Dobrilovic N, Elefteriades JA: Stenting the descending aorta during repair of type A dissection: Technology looking for an application? J Thorac Cardiovasc Surg 131:777–778, 2006
8. Halstead JC, Meier M, Etz C, et al: The fate of the distal aorta after repair of acute type A aortic dissection. J Thorac Cardiovasc Surg 133:127–135, 2007
9. Evangelista A, Salas A, Ribera A, et al: Long-term outcome of aortic dissection with patent false lumen. Predictive role of entry tear size and location. Circulation 125:3133–3141, 2012
10. Rampoldi V, Trimarchi S, Eagle KA, et al: Simple risk models to predict surgical mortality in acute type A aortic dissection: the international registry of acute aortic dissection score. Ann Thorac Surg 83:55–61, 2007
11. Biancari F, Vasques F, Benenati V, et al: Contemporary results after surgical repair of type A aortic dissection in patients aged 80 years and older: A systematic review and meta-analysis. Eur J Cardiothorac Surg 40:1058–1063, 2011

12. Di Marco L, Pacini D, Leone A, et al: Long-term outcome after acute type A aortic dissection: Does an age limit still exist? J Cardiovasc Surg (Torino) 55:359–365, 2014
13. Geirsson A, Szeto WY, Pochettino A, et al: Significance of malperfusion syndromes prior to contemporary surgical repair for acute type A dissection: Outcomes and need for additional revascularizations. Eur J Cardiothorac Surg 32:255–262, 2007
14. Hagan PG, Nienaber CA, Isselbacher EM, et al: The international registry of acute aortic dissection (IRAD): New insights into an old disease. JAMA 283:897–903, 2000
15. Mehta RH, Suzuki T, Hagan PG, et al: Predicting death in patients with acute type A aortic dissection. Circulation 105:200–206, 2002
16. Girdauskas E, Kuntze T, Borger MA, et al: Surgical risk of preoperative malperfusion in acute type A aortic dissection. J Thorac Cardiovasc Surg 138:1363–1369, 2009
17. Tanaka H, Okada K, Yamashita T, et al: Surgical results of acute aortic dissection complicated with cerebral malperfusion. Ann Thorac Surg 80:72–76, 2005
18. Estrera AL, Garami Z, Miller CC, et al: Acute type A aortic dissection complicated by stroke: Can immediate repair be performed safely? J Thorac Cardiovasc Surg 132:1404–1408, 2006
19. Czerny M, Schoenhoff F, Etz C, et al: The impact of pre-operative malperfusion on outcome in acute type A aortic dissection: Results from the GERAADA registry. J Am Coll Cardiol 65:2628–2635, 2015
20. Di Eusanio M, Trimarchi S, Patel HJ, et al: Clinical presentation, management, and short-term outcome of patients with type A acute dissection complicated by mesenteric malperfusion: Observations from the international registry of acute aortic dissection. J Thorac Cardiovasc Surg 145:385–390, 2013
21. Geirsson A, Szeto WY, Pochettino A, et al: Significance of malperfusion syndromes prior to contemporary surgical repair for acute type A dissection: Outcomes and need for additional revascularizations. Eur J Cardiothorac Surg 32:255–262, 2007
22. Yamashiro S, Arakaki R, Kise Y, et al: Management of visceral malperfusion complicated with acute type A aortic dissection. Interact Cardiovasc Thorac Surg 21:346–351, 2015
23. Deeb GM, Patel HJ, Williams DM: Treatment for malperfusion syndrome in acute type A and B aortic dissection: A long-term analysis. J Thorac Cardiovasc Surg 140:S98–S100, 2010
24. Estrera AL, Huynh TT, Porat EE, et al: Is acute type A aortic dissection a true surgical emergency? Semin Vasc Surg 15:75–82, 2002
25. Hughes GC, Zhao Y, Rankin JS, et al: Effects of institutional volumes on operative outcomes for aortic root replacement in North America. J Thorac Cardiovasc Surg 145:166–170, 2013
26. Dewey TM, Herbert MA, Ryan WH, et al: Influence of surgeon volume on outcomes with aortic valve replacement. Ann Thorac Surg 93:1107–1113, 2012
27. Andersen ND, Ganapathi AM, Hanna JM, et al: Outcomes of acute type A dissection repair before and after implementation of a multidisciplinary thoracic aortic surgery program. J Am Coll Cardiol 63:1796–1803, 2014
28. Lenos A, Bougioukakis P, Irimie V, et al: Impact of surgical experience on outcome in surgery of acute type A aortic dissection. Eur J Cardiothorac Surg 48:491–496, 2015
29. Bachet J, Carrel T: Who may operate on acute aortic dissections? The squaring of the circle. Eur J Cardiothorac Surg 48:497–498, 2015
30. Conzelmann LO, Weigang E, Mehlhorn U, et al: Mortality in patients with acute aortic dissection type A: Analysis of pre-and intraoperative risk factors from the German Registry for Acute Aortic Dissection Type A (GERAADA). Eur J Cardiothorac Surg 49:e44–e52, 2016
31. Evangelista A, Isselbacher EM, Bossone E, et al: Insights from the international registry of acute aortic dissection: A 20-year experience of collaborative clinical research. Circulation 137:1846–1860, 2018
32. Poon SS, Theologou T, Harrington D, et al: Hemiarch versus total aortic arch replacement in acute type A dissection: A systematic review and meta-analysis. Ann Cardiothorac Surg 5:156–173, 2016. https://doi.org/10.21037/acs.2016.05.06
33. Larsen M, Trimarchi S, Patel H, et al: Extended versus limited arch replacement in acute type A aortic dissection. Eur J Cardiothorac Surg 52:1104–1110, 2017
34. Di Marco L, Leone A, Murana G, et al: Acute type A aortic dissection: Rationale and outcomes of extensive repair of the arch and distal aorta. Int J Cardiol 267:145–149, 2018
35. Shrestha M, Bachet J, Bavaria J, et al: Current status and recommendations for use of the frozen elephant trunk technique: A position paper by the vascular domain of EACTS. Eur J Cardiothorac Surg 47:759–769, 2015